

April - June 2015

Volume 20

Issue 2

Journal of
Indian Association
of
Pediatric Surgeons

Official Publication of
Indian Association of Pediatric Surgeons

Online at
www.jiaps.com

JIAPS

Esophageal lung resection and prosthesis placement in a preterm neonate

Lalit Parida, Kamalesh Pal, Hussah A. Buainain, Khalid U. Al-Umran¹

Department of Surgery, Division of Pediatric Surgery, ¹Department of Pediatrics, Division of Neonatology, University of Dammam, King Fahd Hospital of the University, Al Khobar, Saudi Arabia

Address for correspondence: Dr. Lalit Parida, Consultant Pediatric Surgeon, Assistant Professor, Department of Surgery, Division of Pediatric Surgery, P. O. Box - 40176, King Fahd Hospital of the University, University of Dammam, Al Khobar - 31952, Saudi Arabia.
E-mail: Lpkfhu@yahoo.com

ABSTRACT

This report describes a successful outcome in a preterm baby with an esophageal atresia and tracheo-esophageal fistula, who initially underwent a primary esophageal repair; but a persistent nonexpanding lung on the side of surgery led to further investigations. A further diagnosis of an esophageal lung resulted in pneumonectomy and prophylactic placement of an intra-thoracic prosthesis to prevent post-pneumonectomy syndrome. To the best of our knowledge, this is the first report of a prophylactic placement of an intra-thoracic prosthesis in a neonate with the condition of esophageal atresia and tracheo-esophageal fistula and associated esophageal lung.

KEY WORDS: Esophageal lung, esophageal atresia, intra-thoracic prosthesis, post-pneumonectomy syndrome, tracheo-esophageal fistula



INTRODUCTION

Esophageal lung is a rare variant of communicating bronchopulmonary foregut malformations (CBPFM). The lung is connected to the esophagus through its main stem bronchus. Absence of the involved ipsilateral main stem bronchus at the level of expected carinal bifurcation exists. An esophageal lung can be differentiated from a pulmonary sequestration, as the former involves the whole lung and receives its blood supply from the pulmonary artery.^[1,2] It can either present in the neonatal period usually in association with esophageal atresia (EA) and tracheo-esophageal fistula (TEF) or later on in life with respiratory complaints. In a rare situation when it is associated with EA/TEF, it becomes a diagnostic challenge.^[3] The affected lung in these cases is usually hypoplastic and will need a pneumonectomy. This can potentially lead to a post-pneumonectomy syndrome.^[4,5] We describe our experience with esophageal lung in a preterm

neonate with long gap EA and TEF, which was managed successfully with pneumonectomy and intra-thoracic prosthesis placement.

CASE REPORT

A 3-day-old preterm neonate (29 weeks gestation, weighing 1060 grams) was admitted with a diagnosis of EA and TEF. A pre-operative chest radiograph revealed an opacification of right lung. A right thoracotomy with division of TEF and primary esophageal repair was done. The right lung was not expanding during the surgery in spite of positive pressure ventilation and had to expedite the procedure considering anesthetic side effects. The tenth post-operative day contrast study revealed a patent esophageal anastomosis without any leak. However, the right lung remained collapsed. A flexible bronchoscopy revealed a single patent ostium on the left side at the level of expected carina (suggestive of left main bronchus) and another collapsing ostium

Cite this article as: Parida L, Pal K, Buainain HA, Al-Umran KU. Esophageal lung resection and prosthesis placement in a preterm neonate. *J Indian Assoc Pediatr Surg* 2015;20:87-9.

Source of Support: Nil, **Conflict of Interest:** None declared.

with evidence of sutures on the right side. These sutures were suggestive of ligated fistula as we were confident that during the first thoracotomy, we had divided only the TEF and placed our sutures at the tracheal end and these were the only sutures placed in that region. A high resolution computed tomography of the chest ruled out any aberrant vascular ring, but suggested the possibility of an absent right main stem bronchus and presence of an air bronchogram from the collapsed right lung towards the lower part of the esophagus almost near the diaphragm level [Figure 1a and b]. A second thoracotomy revealed an intact esophageal anastomosis, but an absent right main bronchus. Exploration of right lung hilum revealed a thick cartilaginous tubular structure (suggestive of right main bronchus) traversing just above the diaphragm towards the lower esophagus [Figure 2]. The entire right lung was unilobar, without any fissures of liver like consistency, and the hilar region revealed a single pulmonary artery and a vein. The bronchial communication was transected from the esophagus and the esophageal defect was closed. A right pneumonectomy was done and an elliptical smooth tissue expander (Mentor™, Irving TX, USA) was used as a lung prosthesis after filling it with 15 ml of saline [Figure 3]. The histopathology of the pneumonectomy specimen revealed congested hypoplastic lung parenchyma. The baby was discharged on full oral feedings. A follow-up visit at the age of one year revealed the baby without any significant respiratory complaints. A chest radiograph showed a normal left lung, centralized mediastinum with presence of prosthesis *in situ* and a degree of scoliosis.

DISCUSSION

Communicating bronchopulmonary foregut malformations has been classified into four types by Srikanth *et al.*^[1] Our patient falls under the category 1A as the entire lung was arising from the esophagus in the setting of EA and TEF. Less than a dozen cases of esophageal lung in association with EA/TEF have been previously reported.^[3]

It is very difficult to establish a diagnosis of esophageal lung at presentation in a newborn with EA/TEF. A white opacification of lung in the chest radiograph will be considered to be either collapse or consolidation of the lung subsequent to possible upper esophageal pouch aspiration. A hypoplastic lung as seen in esophageal lung is less likely to be considered.

Our patient was a 29-week-preterm neonate of around one kilogram when he was taken to the operating room for EA/TEF repair. We did observe that the right lung was not expanding with positive pressure ventilation after division of the TEF and primary esophageal

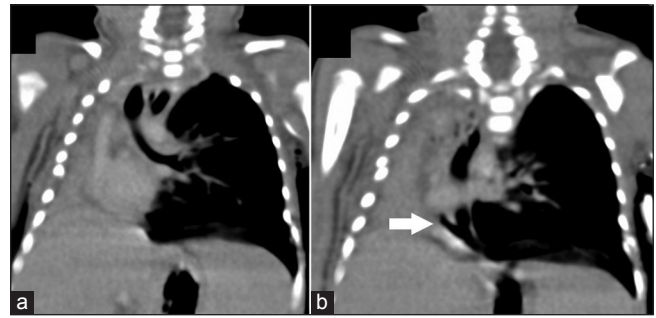

Figure 1: Coronal images of computed tomography scan demonstrating (a) the trachea and left main stem bronchus with absent right main stem bronchus; (b) right sided communication from lower esophagus to the right lung (arrow-communication)

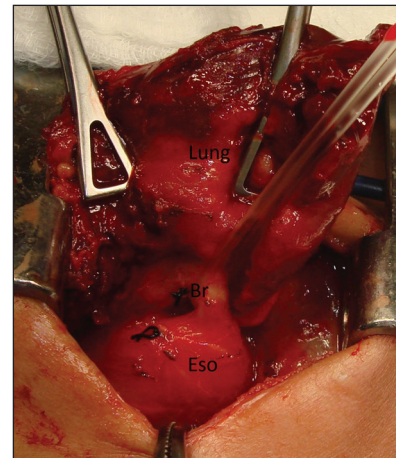


Figure 2: Right main bronchus communicating between the hypoplastic lung and the lower esophagus (Br-bronchus; Eso-lower esophagus)

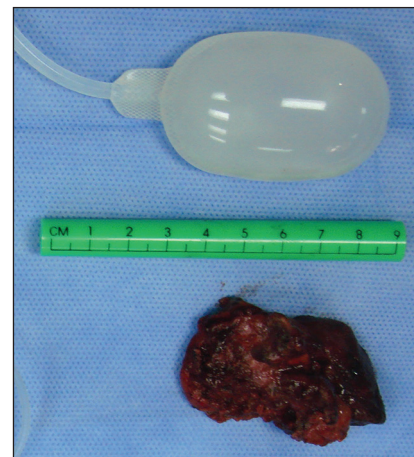

Figure 3: Lung prosthesis with resected right hypoplastic lung

anastomosis. But the rare occurrence of an associated esophageal lung was not considered. In such a situation, it will be a good practice to trace the distal esophagus down to the level of diaphragm to look for any communication arising from it to the lung. This can encourage the surgeon to do an intra-operative esophageal contrast study with the involved lung in

a dependent position to diagnose any communication between the distal esophagus and the lung. The surgeon can then proceed with a pneumonectomy and prosthesis placement in the same operative session. This can be beneficial as the hypoplastic lung gets resected in a single procedure along with the EA/TEF repair and the baby is spared a second thoracotomy considering the fact that pleural adhesions can make the second surgery difficult.

A nonexpanding lung after EA/TEF repair can be investigated by bronchoscopy, high-resolution computed tomography and esophageal contrast studies. A diagnosis of an esophageal lung can be established if a hypoplastic lung is demonstrated to have an esophageal communication along with absent ipsilateral main stem bronchus with pulmonary vessels supplying the involved lung.^[2] The surgeon must be aware of the post-pneumonectomy syndrome in this age group. This happens due to severe mediastinal shifting after a pneumonectomy, which can lead to stretching of the remaining contralateral mainstem bronchus and tracheal compression against the aortic arch. This leads to a possible respiratory failure and is usually observed for several months or even years after the pneumonectomy. An intra-thoracic prosthesis will result in a progressive centralization of the mediastinum and reduce the symptoms of the functional obstruction.^[4] Though previous authors describe placement of the prosthesis after the development of a post-pneumonectomy syndrome, we consider it prudent to place the prosthesis during the same operative session as that

for the pneumonectomy.^[6] This may prevent a possible post-pneumonectomy syndrome in the future.

In conclusion, we consider that an esophageal lung should be considered in the differential diagnosis of a persistently collapsed nonexpanding lung in patients with EA/TEF during the pre-operative and especially during the intra-operative period. To the best of our knowledge, this is the first report of a prophylactic placement of an intra-thoracic prosthesis after pneumonectomy in a neonate with EA and TEF with an associated esophageal lung.

REFERENCES

1. Srikanth MS, Ford EG, Stanley P, Mahour GH. Communicating bronchopulmonary foregut malformations: Classification and embryogenesis. *J Pediatr Surg* 1992;27:732-6.
2. Sugandhi N, Sharma P, Agarwala S, Kabra SK, Gupta AK, Gupta DK. Esophageal lung: Presentation, management, and review of literature. *J Pediatr Surg* 2011;46:1634-7.
3. Chung JH, Lim GY, Kim SY. Esophageal lung diagnosed following the primary repair of esophageal atresia with tracheo-esophageal fistula in a neonate. *Surg Radiol Anat* 2014;36:397-400.
4. Podevin G, Larroquet M, Camby C, Audry G, Plattner V, Heloury Y. Postpneumonectomy syndrome in children: Advantages and long-term follow-up of expandable prosthesis. *J Pediatr Surg* 2001;36:1425-7.
5. Saatvedt K, Hoel T, Westvik J, Lindberg H. Correction of postpneumonectomy syndrome in infants with saline-filled expandable prosthesis. *Interact Cardiovasc Thorac Surg* 2011;13:89-90.
6. Boersma D, Koot BG, van der Griendt EJ, van Rijn RR, van der Steeg AF. Congenital bronchopulmonary foregut malformation initially diagnosed as esophageal atresia type C: Challenging diagnosis and treatment. *J Pediatr Surg* 2012;47:e59-62.